

A Unique Case of Microdontia!

Mudita Chaturvedi*, Renuka Verma*, Akhtar Riaz*, Garima Srivastava**, Saurabh Chaturvedi*

Abstract

Microdontia is hypotrophied sizes of teeth. This condition may be the result of allelic mutations at single gene locus. Alternatively, incompletely penetrant non-allelic genes may show a synergistic effect as expected for a multifactorial trait with interacting gene products. This and similar kindreds may allow identification of genes involved in growth.

Keywords: Microdontia; Synergistic effect; Allergic mutation.

Introduction

Microdontia is a condition in which teeth appear smaller than normal. The most common teeth affected are the upper lateral incisors and third molars.[1] The affected teeth may be of normal or abnormal morphology.

There are 3 types of microdontia:

True Generalized Microdontia

All teeth are smaller in size. This disorder is extremely rare. It has been occasionally reported as a result of pituitary dwarfism, retardation and chemotherapeutic treatment during the developmental stages of teeth.[2]

Relative Generalized Microdontia

There is an illusion of true microdontia.

Microdontia Involving a Single Tooth

Commonly affects the maxillary teeth,

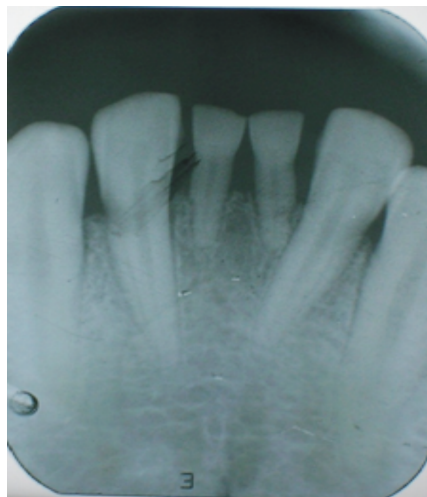
mainly the lateral incisors and third molars. The lateral incisors become peg shaped.

Microdontia involving a single tooth is rather a common condition mainly involving maxillary lateral incisors and third molar.[3] It is clear that reduced or hypoplastic maxillary laterals are a variable expression of the gene for congenitally missing lateral incisors.[4] Maxillary and mandibular premolar being the rarest. Supernumerary teeth, however, are frequently small in size.[5]

Case Report

A twenty three years old male patient reported to the department with a chief complaint of peculiar looking lower front

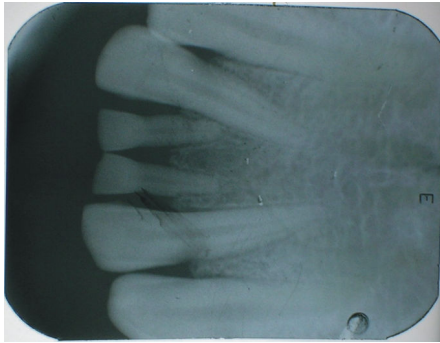
Figure 1



Author's Affiliation: *Senior Lecturar, **Post Graduate Student, Department of Oral Pathology & Microbiology, Career Post Graduate Institute of Dental Sciences & Hospital, Lucknow, Uttar Pradesh, India

Reprints Requests: Dr. Garima Srivastava, 555Kha/99(7), New Ashutosh Nagar, Krishna Nagar, Lucknow Pin code- 226023, Uttar Pradesh, India.

E-mail: garimasri29@gmail.com

Figure 2

teeth, which were smaller in size than their normal counterpart. Intraoral examination revealed microdontia in the mandibular region involving central incisors (31,41) (Figure 1). Extra oral examination however did not reveal any abnormality. Radiographic examination confirmed the diagnosis of microdontia (Figure 2). The medical history did not reveal any presence of systemic disease and he was also not under any medication.

Discussion

Microdontia is a rare shape anomaly that has been used to describe dental dwarfism. Abnormalities in size of teeth and number of teeth are occasionally recorded in clinical cases.[6] This condition may be the result of allelic mutations at a single gene locus.[7] The genetics of this entity remains unclear and several modes of inheritance have been suggested. Alternatively, incompletely penetrant non-allelic genes may show a synergistic effect as expected for a multifactorial trait with interacting gene products. This and similar kindreds may allow identification of genes involved in growth and differentiation of dental tissues by linkage and haplotype association analysis.

Microdontia involving mandibular teeth, is usually associated with systemic disturbances or syndromes such as X linked recessive inheritance, insulin-resistant diabetes, otodontal syndrome, facial hemihyperplasia, KBG syndrome, Ekman-Westborg-Julin

syndrome XYY syndrome. Our case however, was unique in nature because the patient did not reveal any significant history of neither systemic disease nor any related syndrome which is usually associated with microdontia cases as found in literature. The prevalence of microdontia is 0.03–1.9%, with a higher frequency in males. The pathogenetic mechanism underlying microdontia is still unknown.

Depending on their size and morphology, microdonts can create a variety of functional and esthetic problems that may require endodontic, prosthetic, surgical, and/or orthodontic treatment. An interim esthetic restoration can be replaced by a permanent restoration such as a porcelain jacket crown at a later date.[3]

References

1. Kahn, Michael A. *Basic Oral and Maxillofacial Pathology*. 2001; 1.
2. Stewart RE. The dentition. In: *Pediatric Dentistry-Scientific Foundation and Clinical Practice*. London: The C.V. Mosby Company; 1982, 85.
3. Sharma. *Journal Indian Soc Pedo Prev Dent*. 2001; 19(1): 38-39.
4. Van Der Waal I, Van der Kwast WAH. *Developmental anomalies and Eruption disturbances and some acquired disorders of the teeth: Oral Pathology*. Chicago: Quintessence Publishing Co. Inc; 1988, 114.
5. Shafer WG, Hine MK, Levy BM. *Developmental disturbances of oral and paraoral structures: A text book of oral pathology*. Philadelphia: WB Saunders Company; 1993. 37-8.
6. Seema D Bargale and Shital DP Kiran. Non Syndromic occurrence of true generalized microdontia with mandibular mesiodens - a rare case. 2001; 7: 7-19.
7. SP Lyngstadaas, H Nordbo, T Gedde-Dahl, Jr, and PS Thrane. On the Genetics Of Hypodontia And Microdontia. Synergism Or Allelism of major genes in a family with six affected members. *Med Genet*. 1996; 33(2): 137-142.